



MALNUTRITION QUALITY  
IMPROVEMENT INITIATIVE

**MALNUTRITION RECOGNITION GUIDE**

## Two factors in the table below must be present for a malnutrition diagnosis.

	Acute Illness or Injury		Chronic Illness		Social or Environmental Factors	
	Moderate Protein Calorie Malnutrition	Severe Protein Calorie Malnutrition	Moderate Protein Calorie Malnutrition	Severe Protein Calorie Malnutrition	Moderate Protein Calorie Malnutrition	Severe Protein Calorie Malnutrition
<b>Energy Intake</b>	<75% of EEE >7 days	≤50 % of EEE >5 days	<75% of EEE ≥1 month	<75% of EEE ≥1 month	<75% of EEE ≥3 months	≤50% of EEE ≥1 month
<b>Weight Loss</b>	1–2% 1 week 5% 1 month 7.5% 3 months	>2% 1 week >5% 1 month >7.5% 3 months	5% 1 month 7.5% 3 months 10% 6 months 20% 1 year	>5% 1 months >7.5% 3 months >10% 6 months >20% 1 year	>5% 1 month >7.5% 3 months >10% 6 months >20% 1 year	> 5% 1 month >7.5% 3 months >10% 6 months > 20% 1 year
<b>Body Fat Loss</b>	Mild	Moderate	Mild	Severe	Mild	Severe
<b>Muscle Mass Wasting</b>	Mild	Moderate	Mild	Severe	Mild	Severe
<b>Fluid (Edema)</b>	Mild	Moderate to Severe	Mild	Moderate to Severe	Mild	Moderate to Severe
<b>Hand Grip Strength</b>	N/A	Measurably Reduced	N/A	Measurably Reduced	N/A	Measurably Reduced

EEE: Estimated energy expenditure      N/A: Not applicable

Reference: Academy of Nutrition and Dietetics & American Society of Parenteral and Enteral Nutrition Clinical Characteristics Malnutrition 2011.



# Bilateral Muscle Wasting

## Upper Body

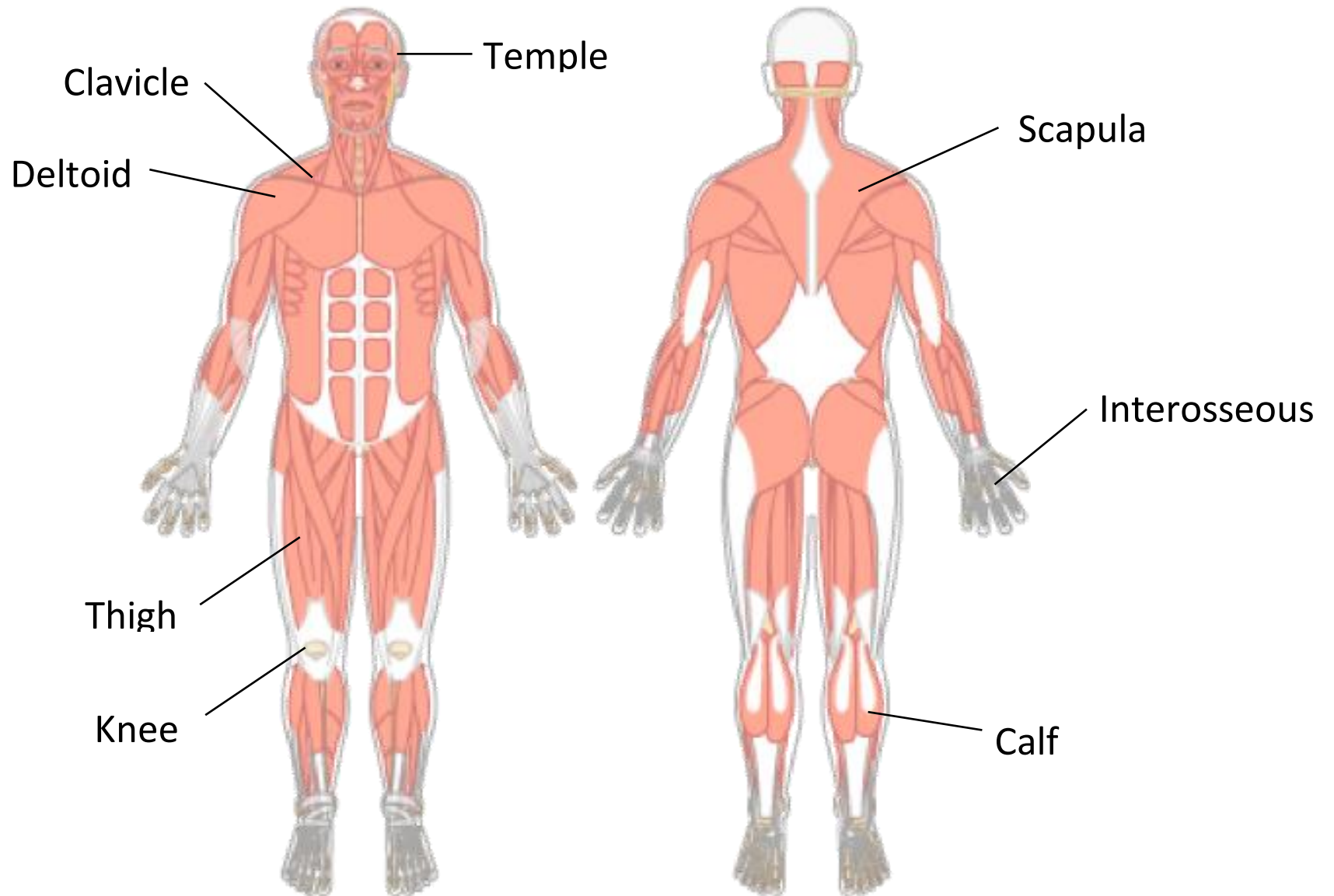
- Temples
- Deltoids (shoulders)
- Clavicles
- Scapula
- Interosseous

## Lower Body

- Thigh
- Knee
- Calf

- More significant than subcutaneous fat loss
- Upper body more susceptible, independent of functional status
- Muscle wasting from inactivity or bedrest most prominent in pelvis and upper legs
- Neurological deficits may produce false-positive findings

# Bilateral Muscle Wasting (continued)



# Bilateral Muscle Wasting: Temples

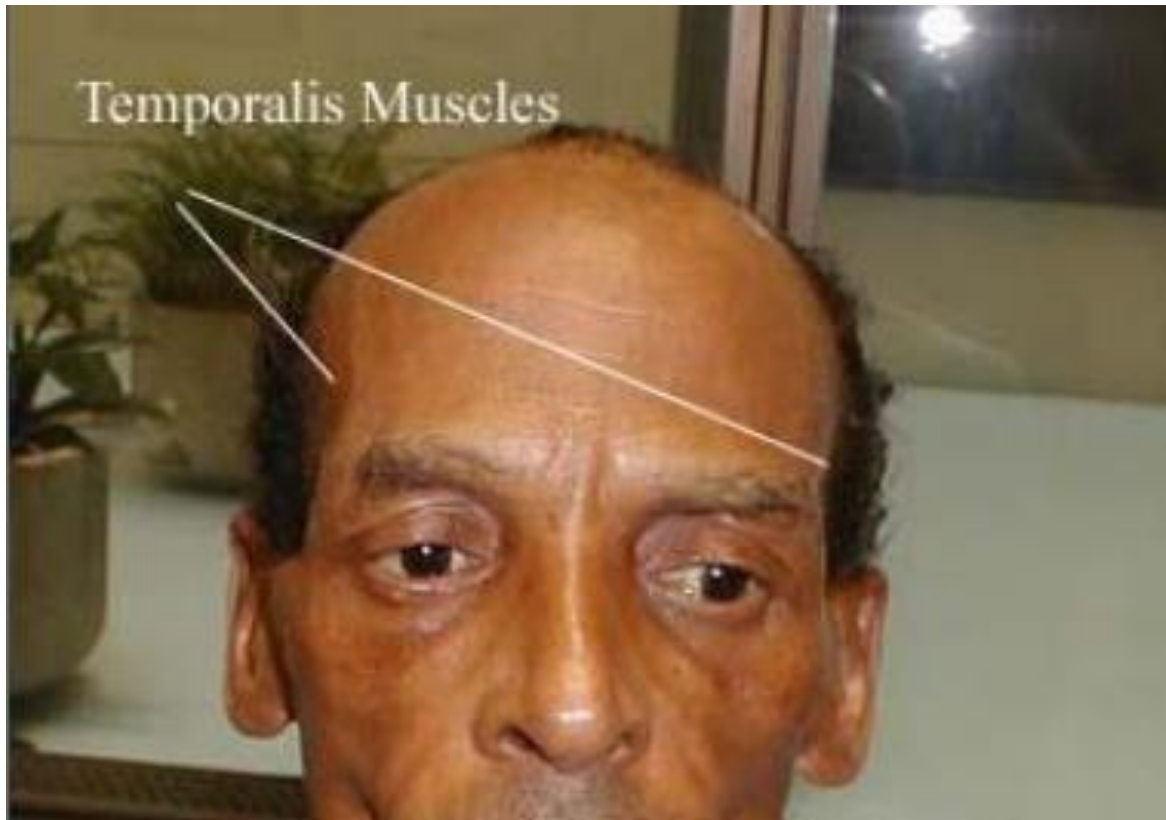
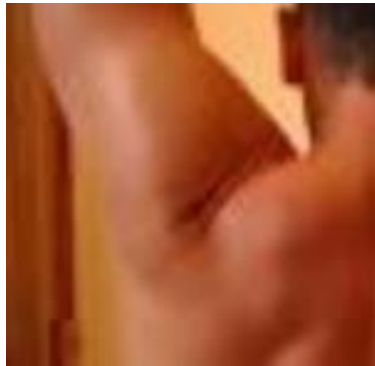
Photo used with permission. University of California, San Diego. Available at:  
[http://meded.ucsd.edu/clinicalimg/head\\_temporal\\_wasting2.htm](http://meded.ucsd.edu/clinicalimg/head_temporal_wasting2.htm). Accessed March 1, 2016.

- Look at patients straight on and have them turn their head from side to side
- Inspect for “scooping” or hollowing of the temporal region
- Such signs indicate wasting of the temporalis muscle

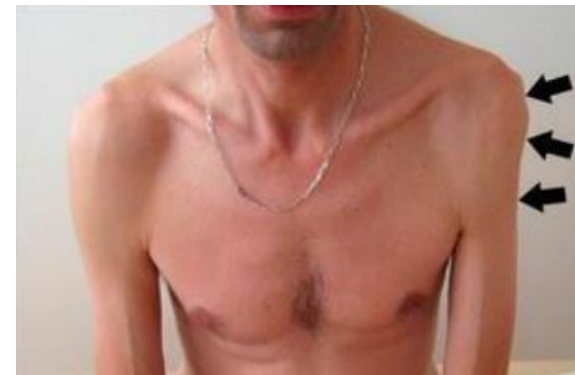# Bilateral Muscle Wasting: Deltoids

Normal



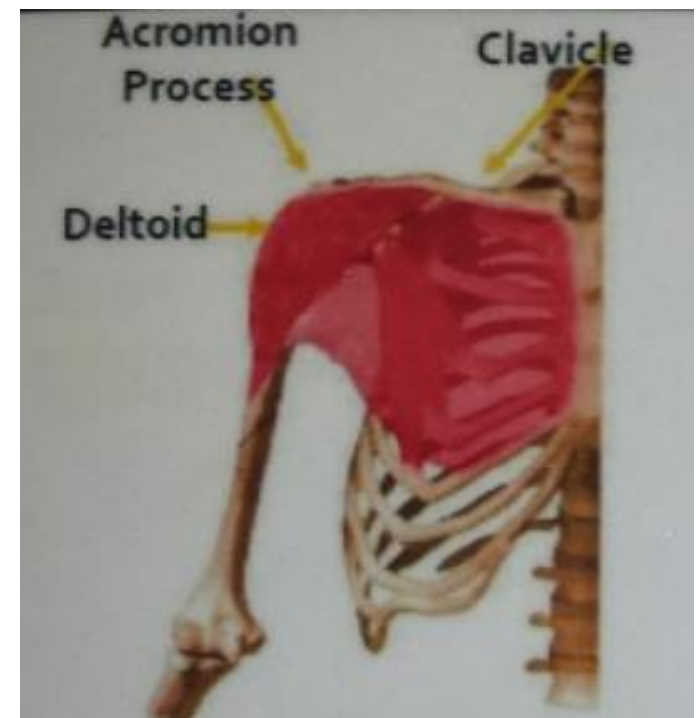
VS.

Severe

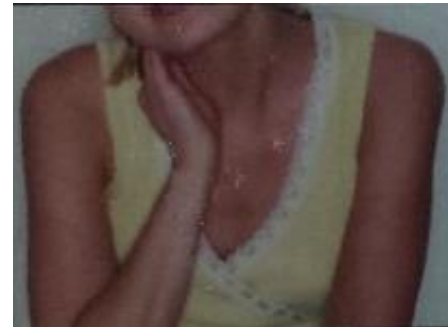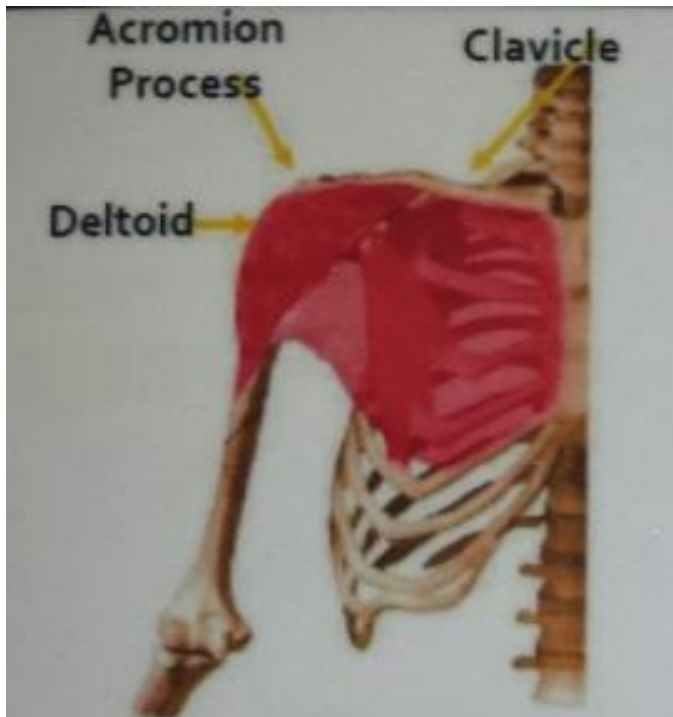


Inspect straight on with patients' arms at side and look for:

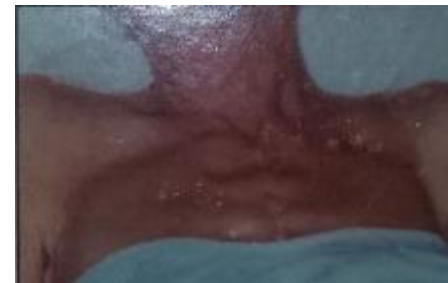- “Squaring” of the shoulders
- Loss of roundness at junction of shoulder and neck
- Loss of deltoid muscle at junction of shoulder and arm
- Acromion process may protrude




# Bilateral Muscle Wasting: Clavicles



**Normal**



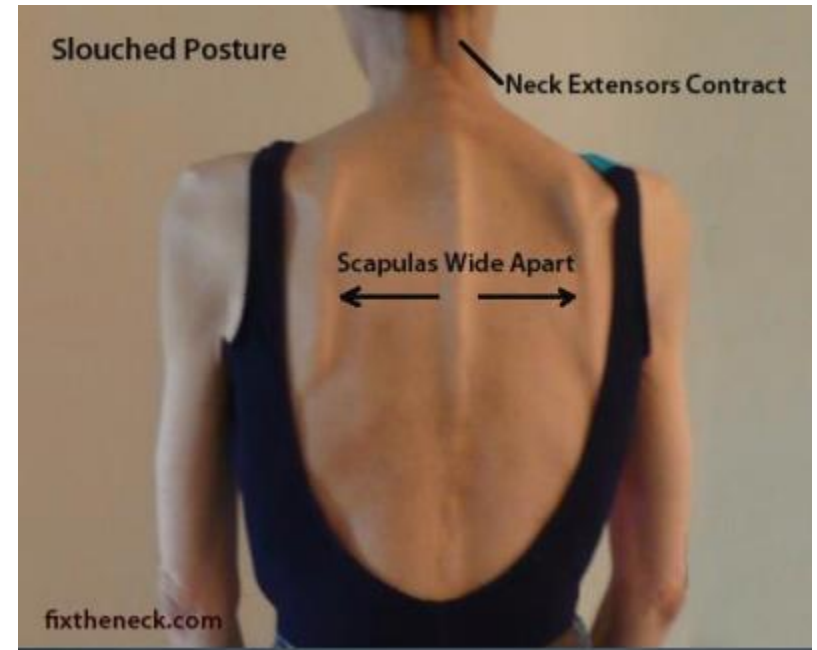
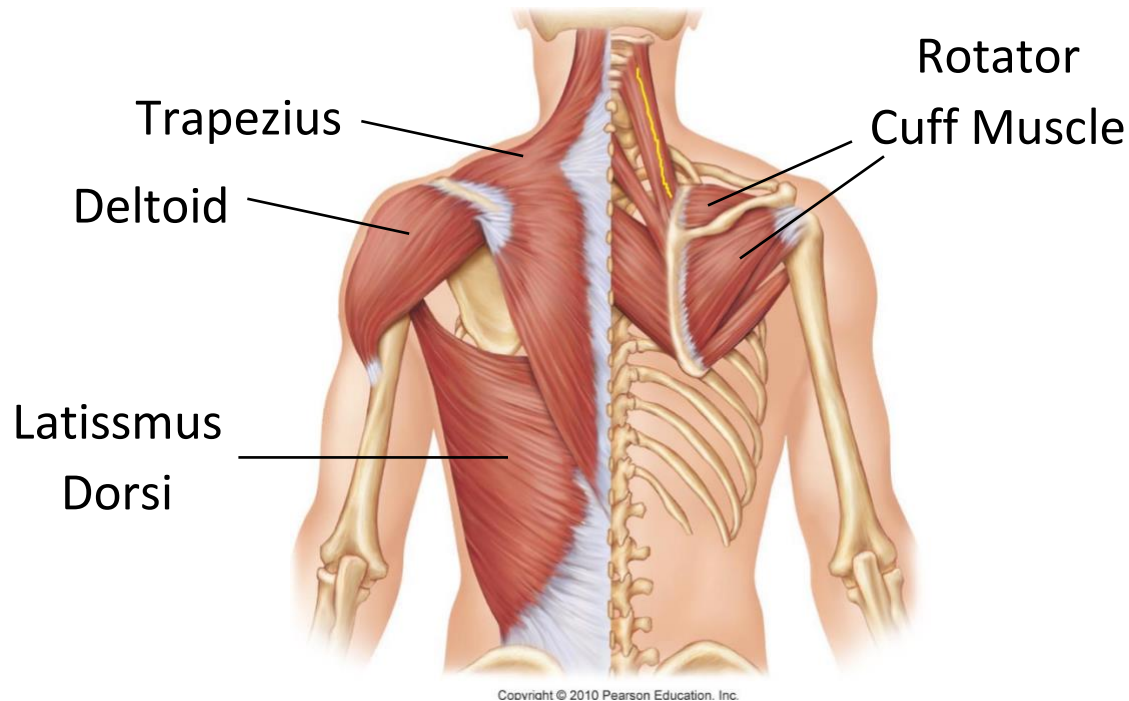
**Moderate**



**Severe**

- Inspect for prominence of bone
- Clavicle less prominent for women
- Indicates wasting of pectoral and deltoid muscles

# Bilateral Muscle Wasting: Scapula



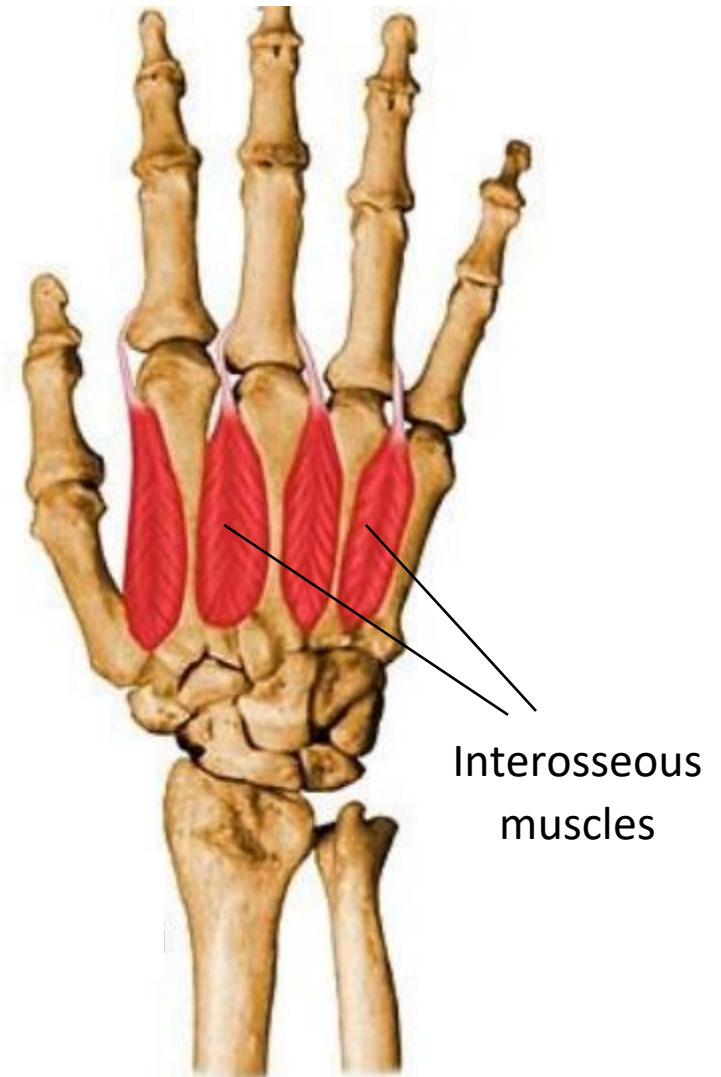
Have patients lift arms and push against hard object:

- Inspect for prominent bones or depression between bones
- Such signs indicate loss of trapezius and deltoid muscles



# Bilateral Muscle Wasting: Interosseous

- Engage muscle by pressing forefinger and middle finger against thumb pad. While engaged, palpate interosseous between forefinger and thumb.
- If unable to engage the muscle, place palm face down with fingers together. Have the patient adduct and abduct the thumb to assess the interosseous muscle.
- For well-nourished patients, the interosseous muscle will bulge with good tone (ie, bounce back) as the thumb is adducted.



# Subcutaneous Fat Loss

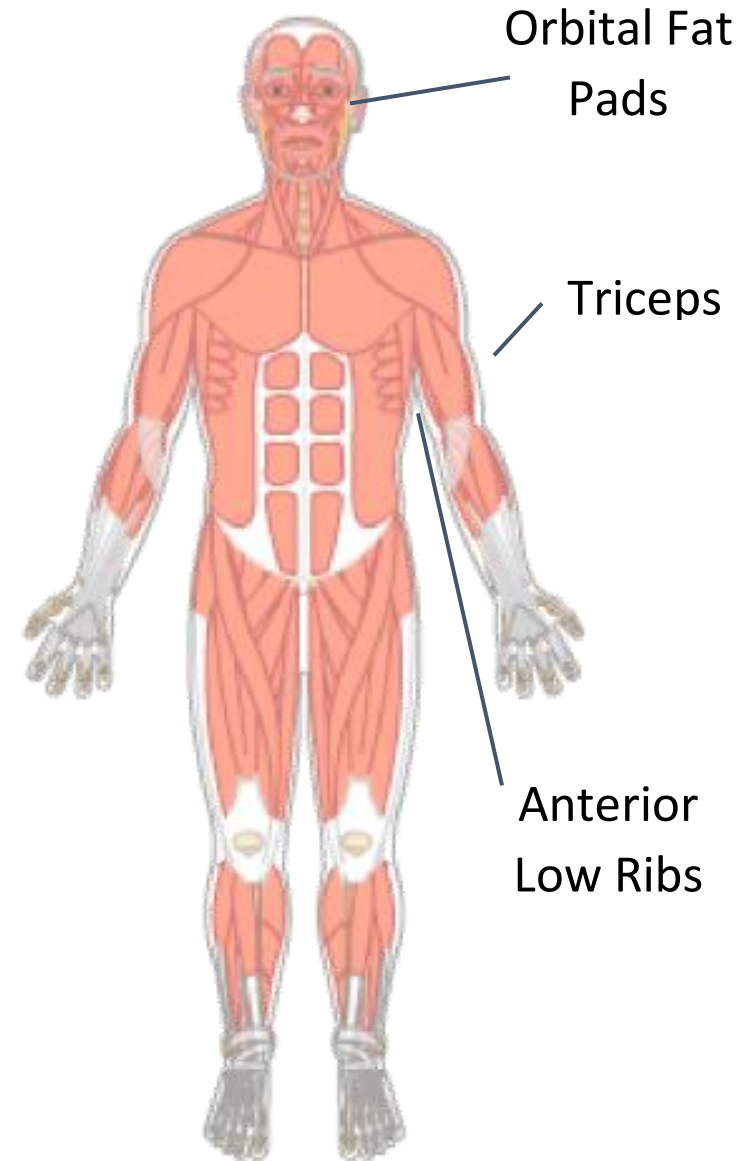
Inspect and palpate areas where adipose tissue is normally present. Look for:

- *Subjective* impressions of loss of fat stores
- Loss of fullness, loose or hanging skin, or hollow appearance

Note: Age-related loss of subcutaneous tissue may confound findings

# Subcutaneous Fat Loss (continued)

- **Orbital Fat Pads**
  - Loss of bulge under eyes (fat pads), characterized by hollow eye
- **Triceps**
  - Palpate (pinch skin) between thumb and forefinger to determine the amount of fat present
- **Anterior Low Ribs**
  - Ribs visible in patients with fat loss



# Subcutaneous Fat Loss: Orbital Fat Pads

**Normal**



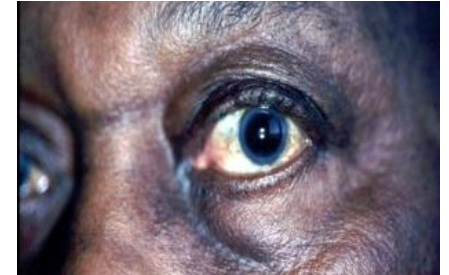Slightly bulged fat pads

**Mild-Moderate**



Slightly dark circle,  
somewhat tired look

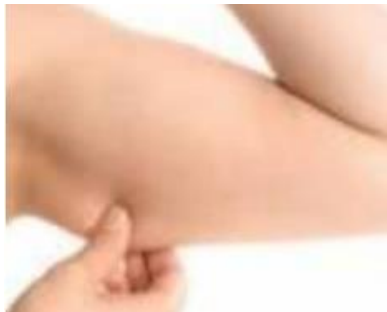**Severe**



Hollow and sunken look,  
dark circles, loose skin

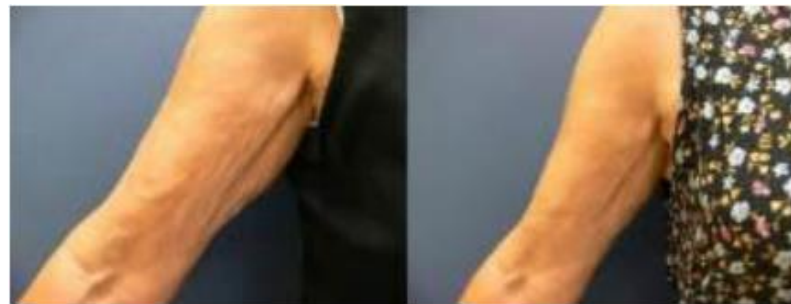# Subcutaneous Fat Loss: Triceps

**Normal**



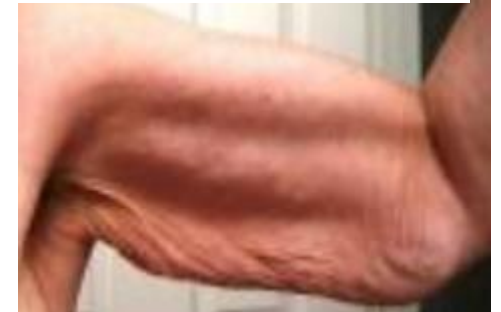Ample fat tissue  
between folds of skin

**Mild-Moderate**



Slightly loose skin; Fingers almost  
touch when pinching skin between  
fingers

**Severe**



Loose skin, very little space  
between skin folds

# Fluid Status

- **Edema**

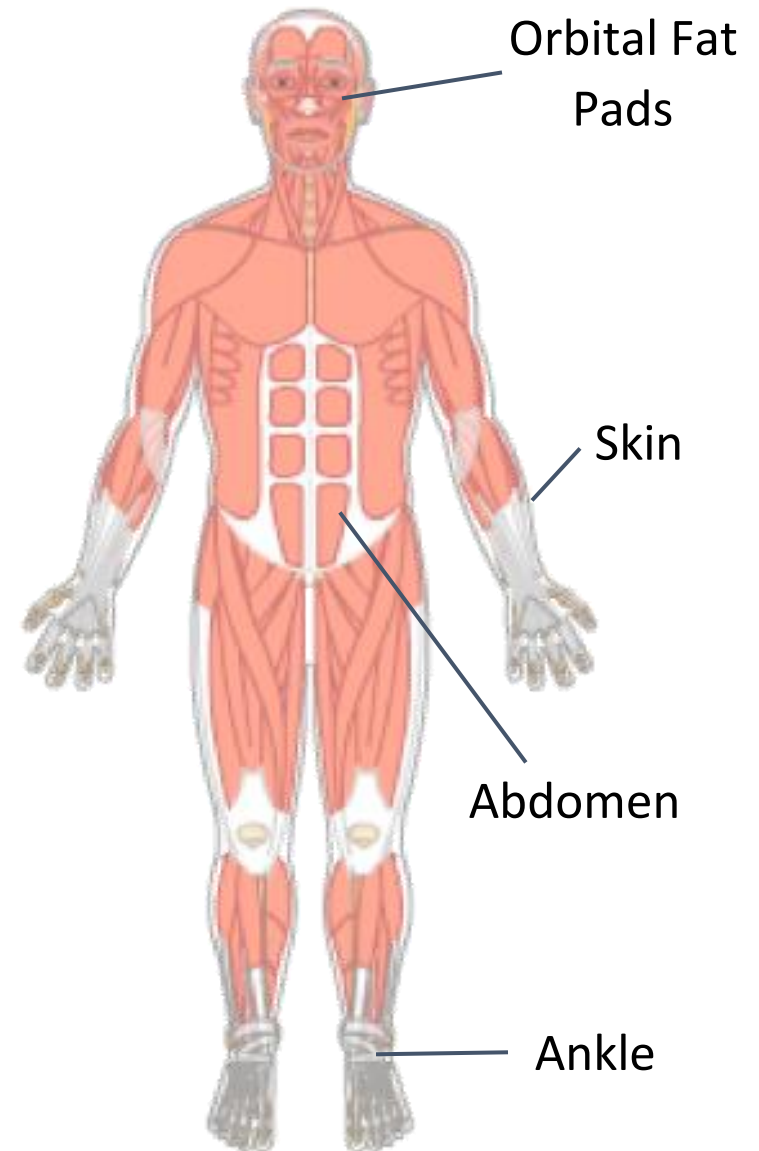
- Dependent areas
- Ankles, sacrum

- **Ascites**

- Abdomen

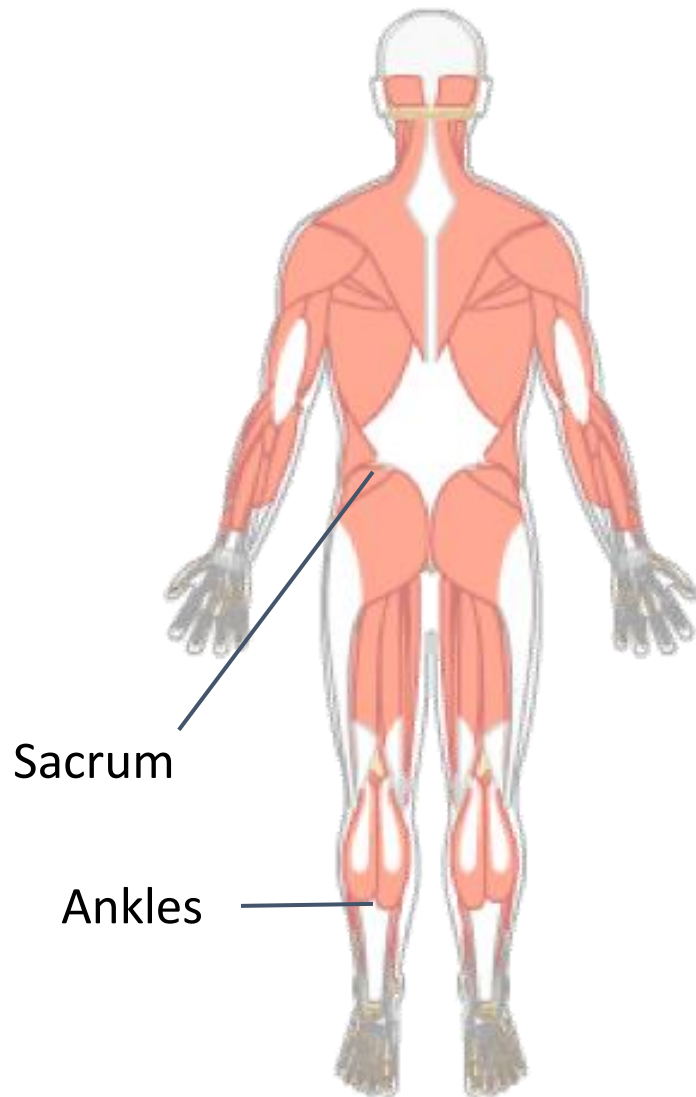
- **Dehydration**

- Orbital area
- Skin

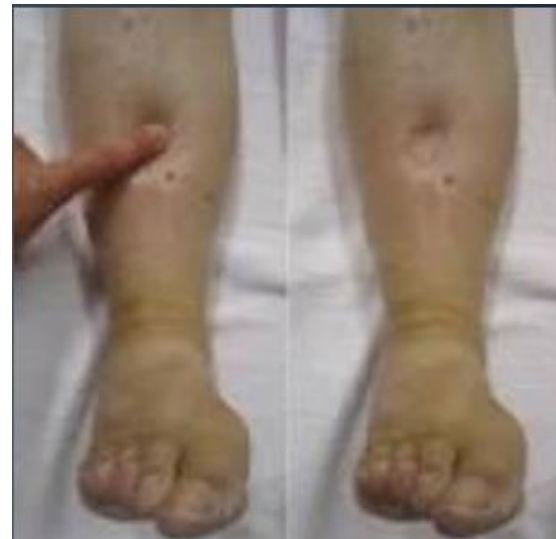

# Fluid Status: Edema

## Dependent Areas

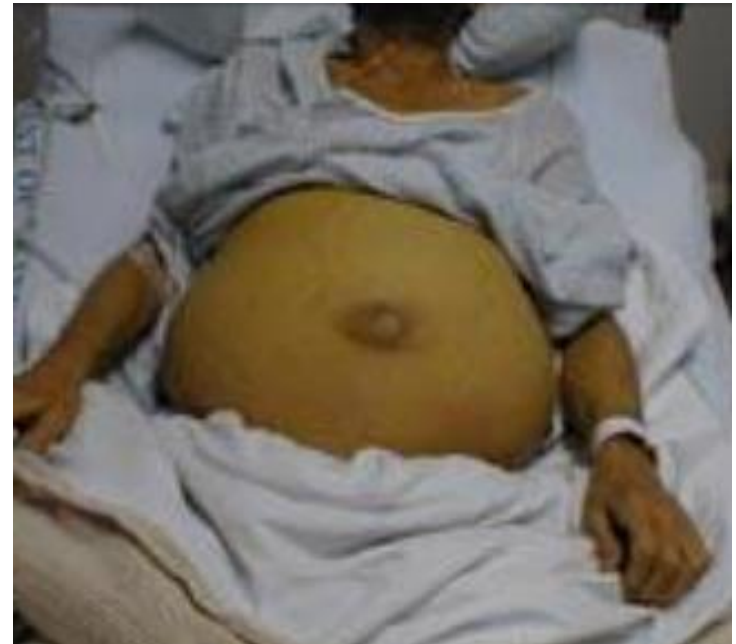

- Inspect for swelling in contour of leg, ankle, or foot
- Palpate by gently squeezing top of foot, ankle, or front of lower leg, or by gently pressing skin in sacral area
- Note if an impression is left



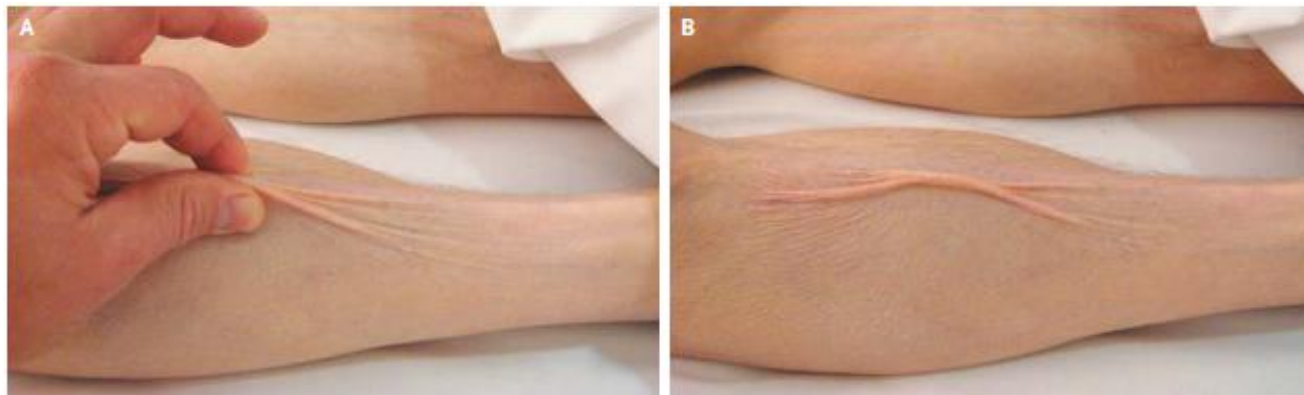
# Fluid Status: Ascites

- Stand at foot of bed, look up toward patient's head, and observe contours of abdomen
- Global abdominal enlargement is usually caused by air, fluid, or fat



# Fluid Status: Dehydration

- Dry or sticky mouth and/or oral mucosa
- Low output of concentrated urine or no urine output
- Dry sclera (decreased tear production)
- Sunken eyes
- Confusion or lethargy
- Poor skin turgor (consider age-related skin changes)



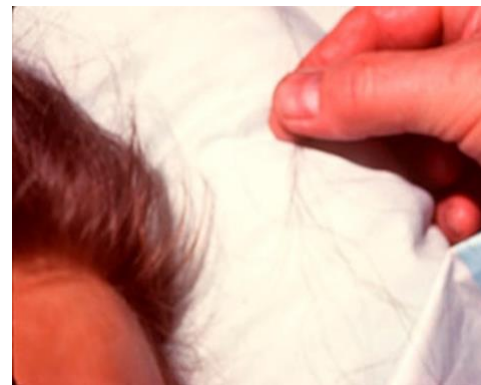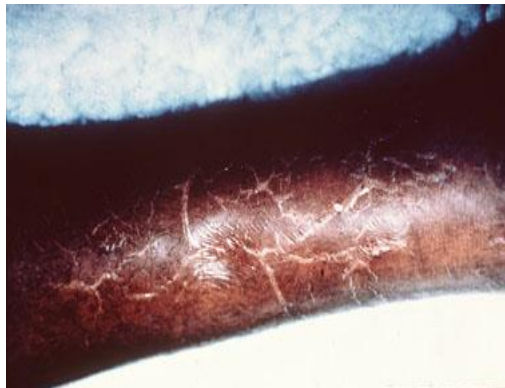
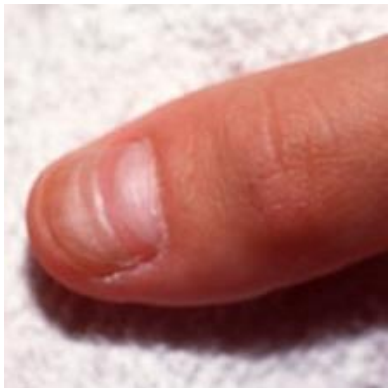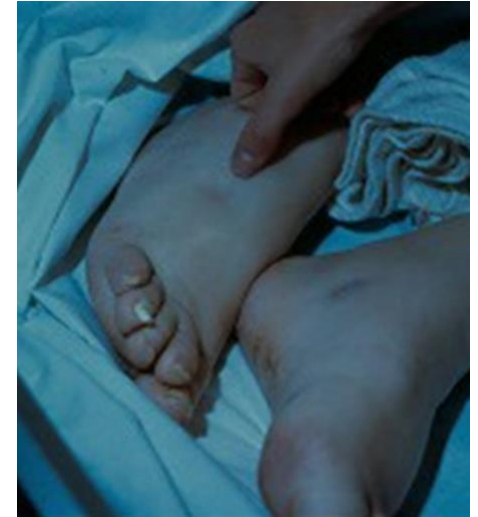
Source: De Vries Feyen et al. "Images in Clinical Medicine: Decreased skin turgor". *NEJM*, 2011; 364:e6. Available at: <http://www.nejm.org/doi/pdf/10.1056/NEJMicm1005144>. Accessed March 1, 2016.



# Protein-Energy Malnutrition (PEM)

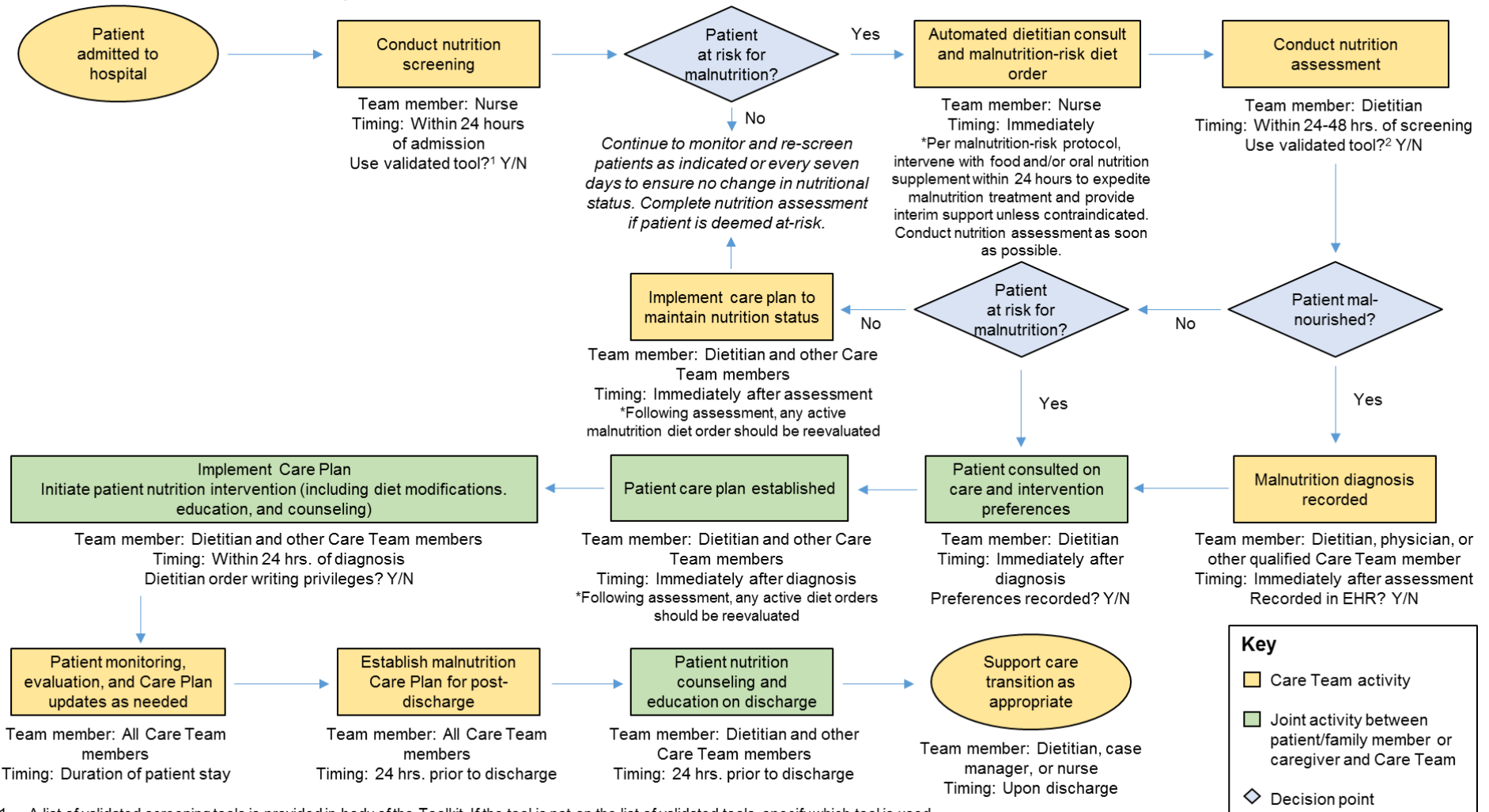
Look for signs of physical PEM, which include:

- Pitting edema
- Dry, flaky, scaly, cracked, bruised, or bleeding skin
- Dull, brittle, and loose hair
- Ridged, cracked, spoon-shaped, or pale nails



# MQii Recommended Clinical Care Workflow

## Malnutrition Care Process – Sample Clinical Workflow



1. A list of validated screening tools is provided in body of the Toolkit. If the tool is not on the list of validated tools, specify which tool is used.
2. A list of validated assessment tools is provided in body of the Toolkit. If the tool is not on the list of validated tools, specify which tool is used.